

TELOMERASE REVERSE TRANSCRIPTASE (TERT) EXPRESSION AND ROLE OF VINCRISTINE SULFATE IN MOUSE MODEL OF MALIGNANCY RELATED PERITONEAL ASCITES: AN EXPERIMENTAL METASTATIC CONDITION

M. Chaklader, P. Das, J.A. Pereira, S. Chatterjee, P. Basak, A. Law, T. Banerjee, S. Chauhan, S. Law*

Stem Cell Research and Application Unit, Department of Biochemistry and Medical Biotechnology,
Calcutta School of Tropical Medicine, Kolkata-700073, West Bengal, India

Aim: To evaluate the efficacy of intraperitoneal vincristine administration into ascitic sarcoma-180 bearing mice as a model of human malignant ascites regarding various peritoneal/retroperitoneal sarcomatosis, and to evaluate the flowcytometric telomerase reverse transcriptase expression for the diagnostic and prognostic purposes. **Methods:** Present study included disease induction by intraperitoneal homologous ascitic sarcoma-180 transplantation followed by *in vivo* intraperitoneal drug administration to study mitotic index, flowcytometric cell cycle and telomerase reverse transcriptase expression pattern, erythrosin-B dye exclusion study for malignant cell viability assessment. Besides, *in vitro* malignant ascite culture in presence and absence of vincristine sulfate and survival study were also taken into consideration. **Results:** Intraperitoneal vincristine administration (concentration 0.5 mg/kg body weight) significantly diminished the mitotic index in diseased subjects in comparison to untreated control subjects. Treated group of animals showed increased life span and median survival time. Cell viability assessment during the course of drug administration also revealed gradual depression on cell viability over time. Flowcytometric cell cycle analysis showed a good prognostic feature of chemotherapeutic administration schedule by representing high G2/M phase blocked cells along with reduced telomerase reverse transcriptase positive cells in treated animals. **Conclusion:** We conclude that long term administration of vincristine sulfate in small doses could be a good pharmacological intervention in case of malignant peritoneal ascites due to sarcomatosis as it indirectly reduced the level of telomerase reverse transcriptase expression in malignant cells by directly regulating cell cycle and simultaneously increased the life expectancy of the diseased subjects.

Key Words: vincristine sulfate, TERT, malignant ascites, peritoneal sarcomatosis, sarcoma 180.

Intra-peritoneal malignancy related ascites (MRA) formation accompanied with peritoneal sarcomatosis or carcinomatosis is a common but fatal consequence of a number of human malignancies [1]. Peritoneal carcinomatosis may arise due to development of tumor in the peritoneal cavity of the patient or tumors of any organ can metastasize into the peritoneum. A number of gynecological tumors such as ovarian, endometrial, cervical cancers and predominately gastrointestinal tract carcinoma in male population, manifest the pathophysiology of MRA formation. On the other hand, peritoneal sarcomatosis related ascite formation involves malignancies like peritoneal leiomyosarcoma, liposarcoma, carcinosarcoma and primary peritoneal spindle cell sarcoma and most of them have primitive mesodermal origin. Interestingly, gastrointestinal stromal tumors are also under the soft-tissue sarcoma family and have the ability to form malignant ascite [2–5]. One unusual example of the peritoneal sarcomatosis is peritoneal Kaposi's sarcoma in HIV patient which can initiate peritoneal malignant ascites as a result of metastasis [6]. Besides, massive liver metastasis may create portal hypertension related ascites with or without inferior vena cava obstruction

or lympho-proliferative disorder can cause chylous ascites formation by obstructing the lymph node [7]. Yet, till to date, it is a clinical challenge for the differential diagnosis between malignant and non-malignant ascites and as well as formation of malignant peritoneal effusion. However, it has been postulated that free cancer cells, exfoliated from cancer lesion are the main cause of peritoneal carcinomatosis or sarcomatosis. MRA remains confined to the intra-peritoneal cavity during most of their natural history and for that reason it is a very interesting characteristic for clinical management of peritoneal malignant ascite/effusion accumulation. Often clinical management depends on disease diagnosis, staging, progression and responses. A number of clinical efforts have been taken into account to manage the malignant ascite, in which surgical debulking of malignant ascitic fluid followed by intraperitoneal administration of chemotherapy are encouraging steps in the current scenario. But, meanwhile, suitable chemotherapy and its efficacy for loco-regional treatment is now a matter of concern, because most of the conventional routes of chemotherapy administration are either intravenous or oral which are very effective but have high risk of side effects too. So, wherever possible local administration of chemotherapy should be taken into account to minimize the exposure of other organs and to diminish the side effects and for that reason we have considered the intraperitoneal route in our study as it involves the peritoneum associated pathology [8–9].

Received: May 16, 2011.

*Correspondence: E-mail: msuj2002@yahoo.co.in

Abbreviations used: ILS – increased life span; MI – mitotic index; MIA – microtubule interfering agent; MRA – malignancy related ascites; MST – median survival time; TC – total cells; TDC – total dividing cells; TERT – telomerase reverse transcriptase.

TELOMERASE REVERSE TRANSCRIPTASE (TERT) EXPRESSION AND ROLE OF VINCRISTINE SULFATE IN MOUSE MODEL OF MALIGNANCY RELATED PERITONEAL ASCITES: AN EXPERIMENTAL METASTATIC CONDITION

M. Chaklader, P. Das, J.A. Pereira, S. Chatterjee, P. Basak, A. Law, T. Banerjee, S. Chauhan, S. Law*

Stem Cell Research and Application Unit, Department of Biochemistry and Medical Biotechnology,
Calcutta School of Tropical Medicine, Kolkata-700073, West Bengal, India

Aim: To evaluate the efficacy of intraperitoneal vincristine administration into ascitic sarcoma-180 bearing mice as a model of human malignant ascites regarding various peritoneal/retroperitoneal sarcomatosis, and to evaluate the flowcytometric telomerase reverse transcriptase expression for the diagnostic and prognostic purposes. **Methods:** Present study included disease induction by intraperitoneal homologous ascitic sarcoma-180 transplantation followed by *in vivo* intraperitoneal drug administration to study mitotic index, flowcytometric cell cycle and telomerase reverse transcriptase expression pattern, erythrosin-B dye exclusion study for malignant cell viability assessment. Besides, *in vitro* malignant ascite culture in presence and absence of vincristine sulfate and survival study were also taken into consideration. **Results:** Intraperitoneal vincristine administration (concentration 0.5 mg/kg body weight) significantly diminished the mitotic index in diseased subjects in comparison to untreated control subjects. Treated group of animals showed increased life span and median survival time. Cell viability assessment during the course of drug administration also revealed gradual depression on cell viability over time. Flowcytometric cell cycle analysis showed a good prognostic feature of chemotherapeutic administration schedule by representing high G2/M phase blocked cells along with reduced telomerase reverse transcriptase positive cells in treated animals. **Conclusion:** We conclude that long term administration of vincristine sulfate in small doses could be a good pharmacological intervention in case of malignant peritoneal ascites due to sarcomatosis as it indirectly reduced the level of telomerase reverse transcriptase expression in malignant cells by directly regulating cell cycle and simultaneously increased the life expectancy of the diseased subjects.

Key Words: vincristine sulfate, TERT, malignant ascites, peritoneal sarcomatosis, sarcoma 180.

Intra-peritoneal malignancy related ascites (MRA) formation accompanied with peritoneal sarcomatosis or carcinomatosis is a common but fatal consequence of a number of human malignancies [1]. Peritoneal carcinomatosis may arise due to development of tumor in the peritoneal cavity of the patient or tumors of any organ can metastasize into the peritoneum. A number of gynecological tumors such as ovarian, endometrial, cervical cancers and predominately gastrointestinal tract carcinoma in male population, manifest the pathophysiology of MRA formation. On the other hand, peritoneal sarcomatosis related ascite formation involves malignancies like peritoneal leiomyosarcoma, liposarcoma, carcinosarcoma and primary peritoneal spindle cell sarcoma and most of them have primitive mesodermal origin. Interestingly, gastrointestinal stromal tumors are also under the soft-tissue sarcoma family and have the ability to form malignant ascite [2–5]. One unusual example of the peritoneal sarcomatosis is peritoneal Kaposi's sarcoma in HIV patient which can initiate peritoneal malignant ascites as a result of metastasis [6]. Besides, massive liver metastasis may create portal hypertension related ascites with or without inferior vena cava obstruction

or lympho-proliferative disorder can cause chylous ascites formation by obstructing the lymph node [7]. Yet, till to date, it is a clinical challenge for the differential diagnosis between malignant and non-malignant ascites and as well as formation of malignant peritoneal effusion. However, it has been postulated that free cancer cells, exfoliated from cancer lesion are the main cause of peritoneal carcinomatosis or sarcomatosis. MRA remains confined to the intra-peritoneal cavity during most of their natural history and for that reason it is a very interesting characteristic for clinical management of peritoneal malignant ascite/effusion accumulation. Often clinical management depends on disease diagnosis, staging, progression and responses. A number of clinical efforts have been taken into account to manage the malignant ascite, in which surgical debulking of malignant ascitic fluid followed by intraperitoneal administration of chemotherapy are encouraging steps in the current scenario. But, meanwhile, suitable chemotherapy and its efficacy for loco-regional treatment is now a matter of concern, because most of the conventional routes of chemotherapy administration are either intravenous or oral which are very effective but have high risk of side effects too. So, wherever possible local administration of chemotherapy should be taken into account to minimize the exposure of other organs and to diminish the side effects and for that reason we have considered the intraperitoneal route in our study as it involves the peritoneum associated pathology [8–9].

Received: May 16, 2011.

*Correspondence: E-mail: msuj2002@yahoo.co.in

Abbreviations used: ILS – increased life span; MI – mitotic index; MIA – microtubule interfering agent; MRA – malignancy related ascites; MST – median survival time; TC – total cells; TDC – total dividing cells; TERT – telomerase reverse transcriptase.

In general, vincristine is a dimeric alkaloid isolated from *Catheranthus roseus*. Vincristine selectively binds to the microtubule and arrests the cells at metaphase stage of mitosis. For this reason vincristine is well known as metaphase blocker. Microtubule interference mediated control of cancer cell proliferation is the basic pharmacology of the vincristine and for that reason it becomes attractive chemotherapeutic agent for many type of cancers [10–13]. Due to its mode of action, vincristine is often recalled as microtubule interfering agent (MIA) and its function is not only limited towards disturbing microtubule assembly and formation of distorted metaphase chromosome but, cytoskeletal changes in cells too [14]. Besides, vincristine also hampers cellular DNA, RNA biosynthesis, lipid biosynthesis, cyclic nucleotide metabolism, glutathione metabolism, interfering with cellular MAPK family signaling pathway, PI3/Akt pathway and a number of cellular gene expression [15–22]. In this scenario, it is possible to provide an appropriate therapy to the patients when proper diagnosis and staging of the malignancies have been carried out successfully by means of certain biomarkers. There are lots of biomarkers for many different types of malignancies. But, what exists for malignant effusion is still questionable. We have chosen telomerase as the differential, and as well as prognostic marker of interest to identify the malignant peritoneal ascites [1, 23, 24]. The reasons behind considering the telomerase as a biomarker are manifolds. Telomerase is basically a specialized reverse transcriptase (RT), which extends telomere by catalyzing the addition of TTAGGG nucleotide repeats to the 3' terminus of a chromosomes DNA; lagging strand is then duplicated by DNA polymerase. It exists in primitive protozoan *Tetrahymena* to most advance vertebrate human being [25]. Telomerase appears as a complex of proteins and its catalytic portion is composed of two molecules of each component: a rate limiting enzyme, telomerase reverse transcriptase or TERT; an RNA template encoded by TERC; and dyskerin encoded by DKC1. In the present study we considered telomerase activity in the form of TERT expression, which is linked to the cellular immortality. Telomerase is inactive in most of our tissues except germ cells and stem cells. But, interestingly it is actively expressed in nearly 85% malignancies [26–29]. In our study we described the immunofluorescence based flowcytometric TERT expression pattern instead of Telomerase Repeat Amplification Protocol (TRAP) assay [28]. Besides, flowcytometric based TERT expression study is much more sensitive, semi-quantitative and rapid than TRAP assay. Overall, in our present study we attempted to evaluate the effect of vincristine administration on malignant peritoneal sarcomatosis related ascites through cell viability, mitotic index, cell cycle study, survival study in correlation with TERT expression pattern.

MATERIAL AND METHODS

Animals. 10–12 weeks old male Swiss albino mice (*Mus musculus*) weighing 20 to 24 g were selected from an inbred colony maintained under controlled room temperature ($22 \pm 2^\circ\text{C}$) in the animal house of the Calcutta School of Tropical Medicine. During the course of the study the animals were fed on a diet consisting of 25.0% protein, 10.0% fiber, 5.0% fat, 9.0% minerals and access to water *ad libitum*, under standard conditions with a 12 h light dark period. Maximum six animals were housed in cage containing sterile paddy husk as bedding through out the experiment. The procedures followed were in agreement with the approved guide for the care and use of laboratory animals and Institutional Animal Ethical Committee (IAEC).

Disease induction by sarcoma-180. In this experiment, Crocker's sarcoma (ascitic sarcoma-180) was considered as our malignant peritoneal ascites. The ascitic fluid was drawn using an 18-gauge needle into sterile syringe. 100 μL of ascitic fluid was tested for microbial contamination. Then viability was determined by erythrosin-B exclusion test and cells were counted using hemocytometer. The ascitic fluid was suitably diluted in sterile phosphate buffer saline to get a concentration of 3×10^6 cell/ml of ascitic suspension. This was injected intraperitoneally to obtain malignant ascitic effusion with in 12 to 14 days.

Chemotherapy administration in-vivo. Animals were divided into two groups (N = 6/group). One group acted as sham control, received 0.01 ml/kg of body weight normal saline intraperitoneally, while the other group (N = 6/group) was treated with sterile vincristine sulfate (Sigma) solution (stock concentration 1 mg/ml) and the volume of the drug was kept to 0.01 ml/g (concentration 0.5 mg/kg body weight) [30]. Vincristine was administered intraperitoneally, five days a week after full growth of intraperitoneal ascites and total ten doses were administered for 2 weeks to study the effect.

Metaphase arrest and mitotic index. Cytostatic treatment of vincristine causes metaphase arrest of malignant peritoneal ascites within 90 min of drug administration. Then the peritoneal ascitic fluid was collected by aspiration and washed by normal saline (0.9% NaCl) followed by further processing in hypotonic solution of 0.075 M KCl at 37°C for about 15–25 min. Thereafter, cells were treated with acetic-methanol (1 : 3) fixative solution following vigorous vortex to avoid the cell coagulation. This process was repeated for three times to fix more number of cells. Then slides were properly made following fixation by heat and Giemsa staining.

Mitotic indexing.

Mitotic index (MI) = $\text{TDC} \times 100 / \text{TC}$ (where TDC = total dividing cells, TC = total cell)

Survival study. Chemotherapeutic efficacy can be accessed by median survival time (MST) and increased life span (% ILS) of tumor-bearing animals.

$\%ILS = \text{MST of treated group} - \text{MST of control group} \times 100 / \text{MST of control group}$.

Enhancement of life span (25% and above) of treated group over the control was considered as effective antitumor response.

In-vitro cell culture assay. For the short term malignant ascite culture, peritoneal malignant ascitic cells were suspended in RPMI-1640 at a concentration of 2×10^6 cells/ml of media, supplemented with 15% fetal bovine serum (FBS) (Lonza), 100 U/ml penicillin (Sigma), 100 U/ml streptomycin (Sigma). Total six 35 x 10 mm Petri dishes were divided equally between vincristine treated group (concentration of vincristine was same as i.p *in vivo* dose and volume kept at 3 μ L for each plate) and normal saline treated control group followed by plating with 3 ml of media containing 2×10^6 cells and placed in a CO₂ incubator at 37 °C and 5% CO₂ atmosphere. After 24 h using an inverted microscope the culture plates were compared and photographed.

Erythrosin-B dye exclusion study. About 12–14 days, 1.0 to 2.0 ml of malignant ascitic fluid was collected from control and vincristine treated animals and diluted in phosphate-buffered saline (PBS) to a cell density of 1.0×10^6 /ml (1.4×10^6 /0.7 ml). The survival rate of tumor cells was evaluated by the erythrosin-B (Sigma) dye exclusion method using a hemocytometer (Rohem India) under an optical binocular light microscope (x400 magnification, Olympus).

Flowcytometric analysis of malignancy related ascites (MRA).

Analysis of cell cycle pattern. Flowcytometric cell cycle pattern was studied from vincristine treated and vincristine untreated control cell population by propidium iodide staining kit according to manufacturer instruction. Here, 20,000 events were analyzed by BD-FACS Callibur (Becton Dickenson, USA), using Cell Quest Pro software.

Analysis of telomerase expression. Telomerase expression pattern in peritoneal MRA with *in vivo* vincristine treated and untreated conditions were studied by 15 min 1% para-formaldehyde fixation and permeabilization by 90% ice-cold methanol followed by intracellular TERT staining as described later. Samples were incubated for 30 min with 2 μ L rabbit anti-TERT antibody (Santa Cruz Biotechnology, USA) followed by addition of 2 μ L anti rabbit IgG-Alexafluor-488 (Invitrogen, USA) and incubated further in dark for 30–35 min. Excess fluorescence was then washed off with PBS. Samples were analyzed by BDFACS Callibur (Becton Dickenson, USA) using CellQuestpro software.

Statistical analysis. All the value of mitotic index, TERT expression and cell cycle data were expressed as mean \pm SD (standard deviation). Statistical analysis was performed by paired t-test and consider $2\alpha = 0.05$.

RESULTS

Metaphase arrest and mitotic indexing.

In order to evaluate the efficacy of the administered cytostatic chemotherapy, microscopic observation

of metaphase-arrested cells and their mitotic indexing are classical dependable method of choice. In our study, we found that untreated experimentally induced peritoneal effusion bearing mice had 60.57 ± 1.91 % mitotic index in comparison to vincristine treated mice, which had 39.69 ± 1.69 % mitotic index (Fig. 1) which are statistically quite significant ($P < 0.0001$, $2\alpha = 0.05$), as determined by paired t-test. Besides, microscopic observation revealed that treated peritoneal ascites had serious distorted chromosome in comparison to untreated peritoneal ascites (Fig. 2, a–d).

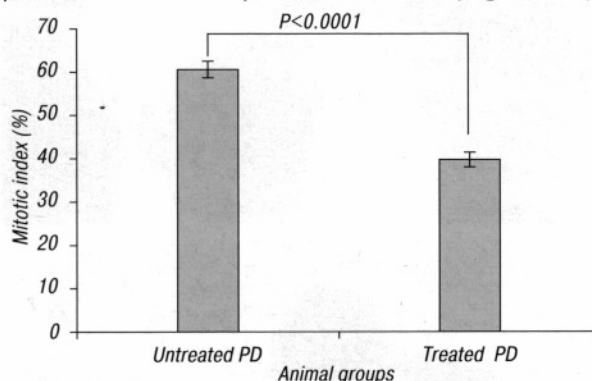


Fig. 1. Graphical representation shows the mitotic index (MI) of untreated (control) and vincristine treated malignant peritoneal effusion. Experimentally induced untreated peritoneal effusion had 60.57 ± 1.91 % MI in comparison to vincristine treated, which had 39.69 ± 1.69 % MI ($P < 0.0001$)

Median survival time (MST) and increase in life span (% ILS). MST and ILS, have become very relative in the course of malignancy progression and its response towards antimalignancy therapy. MST value of vincristine treated group was 11 days and survival range was 4 to 32 days while MST of control group was only 3 days and survival range up to 3 to 11 days. Chemotherapy was administered 10 days after induction of peritoneal effusion. Vincristine treated group had shown 57% increment of their life expectancy in comparison to vincristine untreated group (Table).

Table. Effect of vincristine sulphate on median survival time (MST) and increased life span (% ILS) of treated peritoneal effusion bearing mice and untreated control mice

Groups	Amount of drug	MST (days) (survival range)	ILS (%)
Control (normal saline)	0.01 ml/g b.wt	7 (3–10)	—
Vincristine treated	0.01 ml/g b.wt	11 (4–32)	57.00

In vitro cell culture based assessment of vincristine efficacy.

Cell culture based evidence suggested that vincristine might be useful therapeutic in case of malignant peritoneal effusion with properly evaluated dosimetry because vincristine can not arrest a cell in metaphase for a long period of time. However, we found that in our peritoneal ascites culture, vincristine treatment lowers the cell density in Petri dishes and diminishes the cell viability (Fig. 3, a–d).

Erythrosin-B dye exclusion study for cell viability test.

In this study, control animals showed more or less consistent cellular viability with little variation over the period of 0 h (97.74 %), 24 h (96.64%), 48 h (98%) and 72 h (97.79%) respectively. In contrast, treated sample showed 89.35% viability at initial 0 h, then the cellular viability gradually decreased over

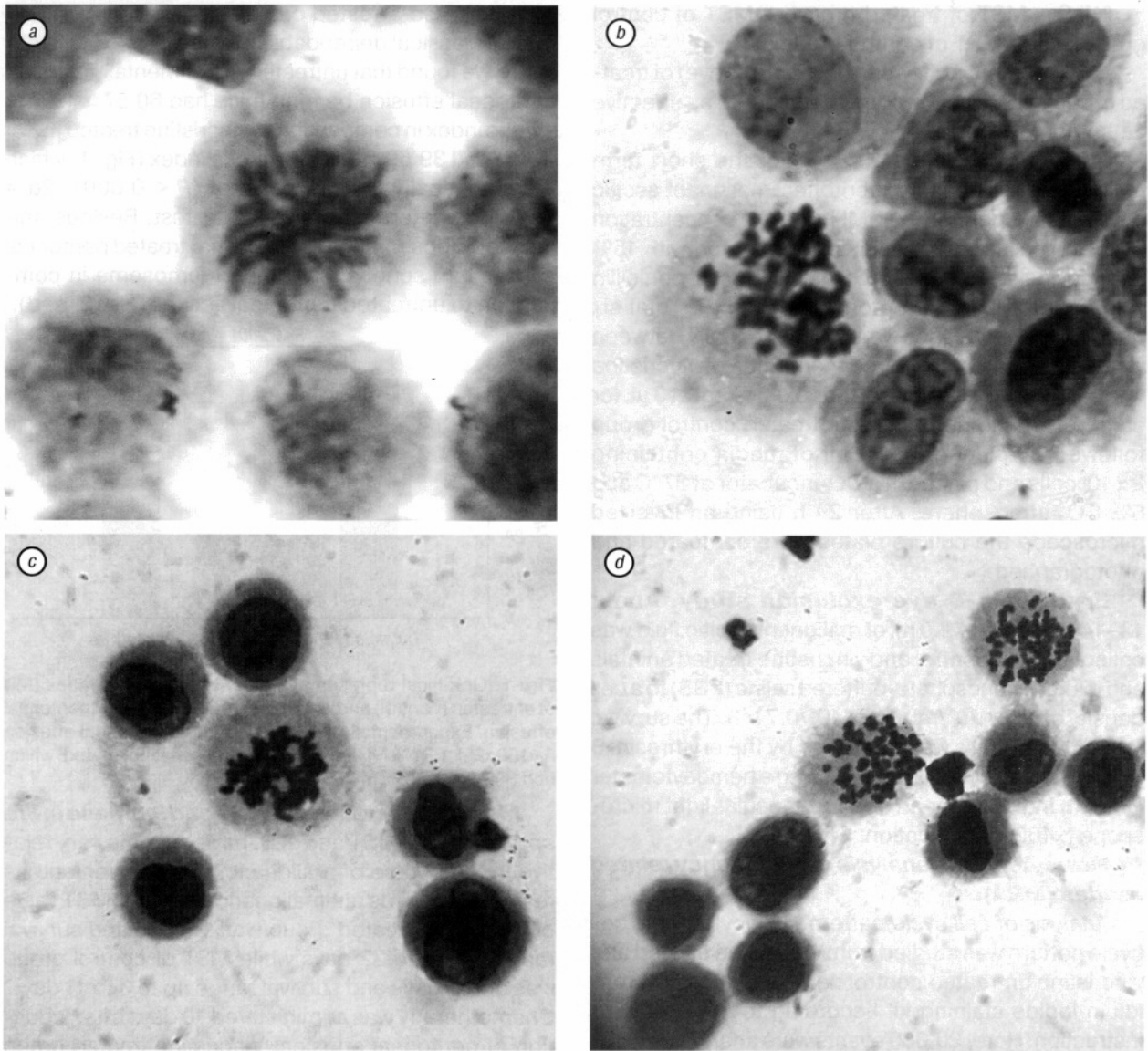


Fig. 2. Untreated malignant peritoneal ascitic cells with clear metaphase chromosome arrangement in cellular equatorial plane. The chromosome arrangement showed multipolar chromosome movements during anaphase (a). Vincristine treated malignant ascitic cells with disorganized metaphase chromosomes and a few broken chromosomes were scattered inside the cytoplasm. Chromosomes were not in cellular equatorial plane rather the whole bunch of chromosomes shifted to one side of the cell (b). Anaphase movement in untreated malignant ascitic cells showed a more or less perfect equipartitioning of the daughter chromosomes (c). Showed an unusual anaphasic movement in vincristine treated malignant ascitic cells with a few chromosomes in lagging condition (d)

the time span of 24 h (74%), 48 h (66.03%) and 72 h (65.31%) (Fig. 4). It correlated well with the efficacy of the vincristine treatment.

Flowcytometric cell cycle and TERT expression analysis of malignancy related ascites. Comparative flowcytometric cell cycle and TERT expression analysis of malignant ascites revealed an initial (0 h) increment $86.34\% \pm 0.2$ of G2/M phase arrested cells in treated group in comparison to control subject where G2/M phase was $8.8\% \pm 0.06$ (Fig. 5). But, the proportion of G2/M phase cells of treated group came at $75.16\% \pm 0.5$ in 24 h and our chemotherapy schedule of five days a week kept that proportion of malignant cells in a stable manner and ultimately stalled to $60.85\% \pm 0.12$ at the second week of the experiment. It is noteworthy that proportion of G1/S phase cells also varied with time in treated group and it was distributed as follow: $13.8\% \pm 0.2$ in 0 h, $24.75\% \pm$

0.16 in 24 h and $39.08\% \pm 0.07$ in 2nd week. Whereas, control group showed an indifferent proportion $91.25\% \pm 0.16$ of G1/S distribution during experiment. On the other hand, initial TERT expression of both control and treated sample showed $99.36\% \pm 0.35$ and $99.21\% \pm 0.60$ positivity, while after 24 h of vincristine administration, treated sample showed little decrease ($97.28\% \pm 0.01$) in TERT expression followed by sharp decrease to $79.63\% \pm 0.04$ after end of the 2nd week (see Fig. 5).

DISCUSSION

Peritoneal ascites may arise due to various reasons and in the present study we emphasized on the formation of peritoneal and retroperitoneal sarcomatosis related ascites in syngenic adult swiss albino mice. Our experimental focus is on the mammalian setting for enhanced medical relevance of dispersed type of malignancy or malignant peritoneal effusion due to metastasis of primary neoplastic sarcomatous

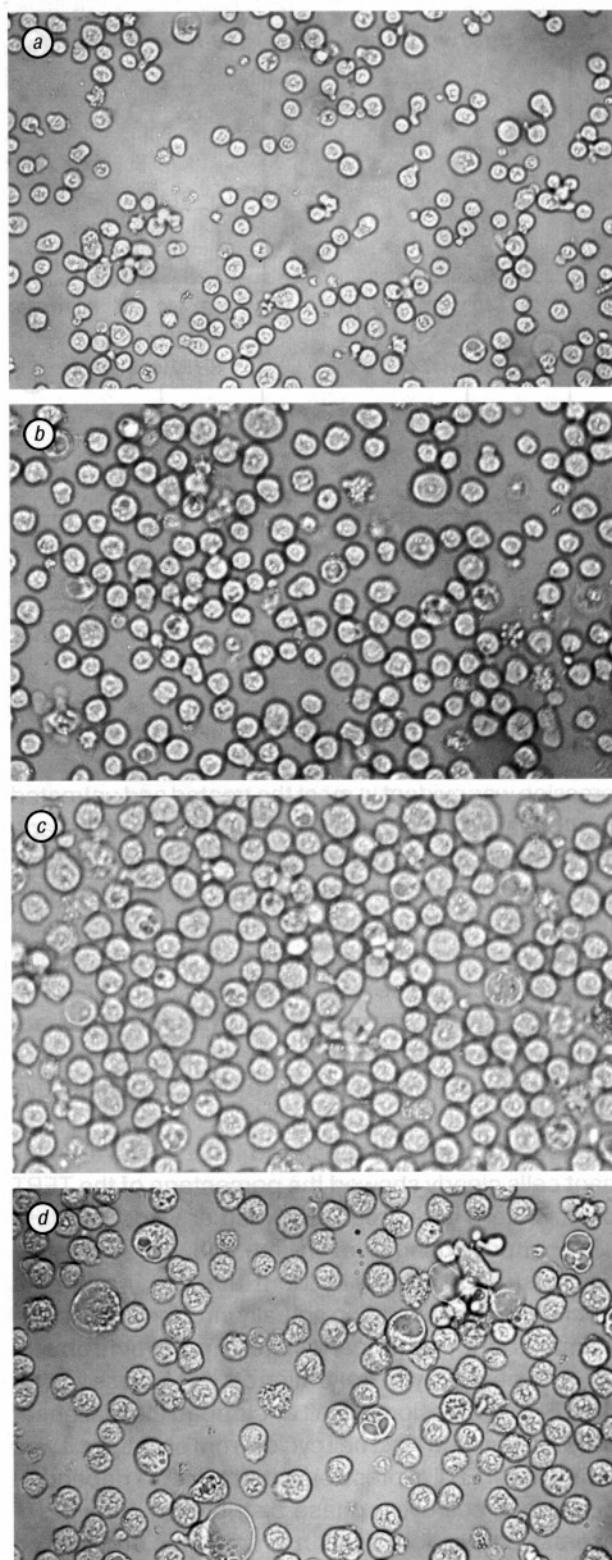


Fig. 3. a: 0 h or initial picture of untreated malignant peritoneal ascitic cell culture; b: 0 h picture of vincristine treated malignant peritoneal ascitic cell culture; c: 24 h picture showed huge malignant clones and no contact dependent inhibition in untreated sample; d: vincristine treated sample exhibited slow growth with signs of cellular apoptosis

growth. We used sarcoma-180 ascitic tumor as a malignant peritoneal effusion model.

Malignant ascites are dispersed type of cancerous cell population confined into peritoneum and simultaneously become a challenge toward all clinicians for differential identification from non-malignant ascites.

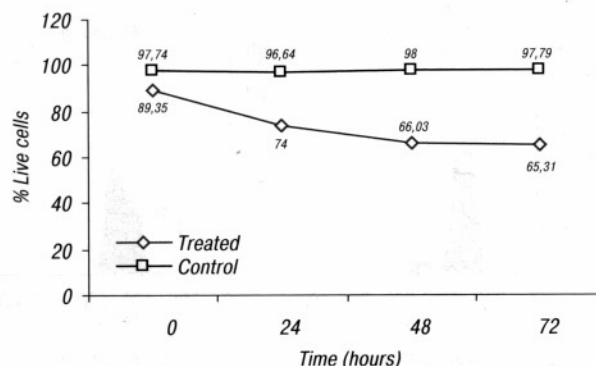


Fig. 4. Erythrosin B dye exclusion study for cellular viability. Control animals showed more or less consistent cellular viability with little variation, in contrast to treated samples where the cellular viability gradually decreased over the time span

Differential identification between malignant and non-malignant ascites in patient is very important for the proper pharmacological management of this critical situation. Till to date there is no perfect non invasive remedy instead of surgical debulking of ascitic fluid. In our work, intraperitoneal vincristine sulfate administration increased life span (57%) of experimental animal in comparison to the animal group, which received only intraperitoneal normal saline solution as control. Increased median survival time (MST) of vincristine treated malignant peritoneal effusion bearing mice was due to the optimum and uniform concentration of vincristine sulfate in the peritoneal cavity through intraperitoneal rather than the intravenous administration. Effects of intraperitoneal vincristine administration sharply decreased the viability of the malignant ascites over the time frame in comparison to the control subject, which did not experienced the challenge of mitotic blocker like vincristine. Moreover when we subjected the malignant ascites in *in vitro* culture with and without vincristine sulfate it was cleared that treated culture lost its cell density over 24 h duration and became prone to cell death. Thus vincristine sulfate might have bound to malignant cells and inhibited cell proliferation by altering the dynamics of tubulin addition to microtubules and this statement is supported by our comparative study of mitotic index (MI) between treated and untreated animal groups. Vincristine treatment gave usual metaphase block and low MI (39.69%) in comparison to the untreated group of animals having high MI (60.57%) (see Fig. 1). Low mitotic index is the indicator of impaired mitosis due to microtubular dynamic instability. Microtubule dynamics plays a critical role in equi-partitioning of chromosomes to the two daughter cells by the mitotic spindle formation. Vincristine mediated mitotic block is failure of the microtubules to capture all the chromosomes at a time and lead to aberrant spindle-chromosome arrangement (see Fig. 2, b, d) in malignant peritoneal ascites. Microtubule assembly inhibition by low vincristine concentration occurs at very low “vincristine to tubulin” ratio, i.e., sub-stoichiometric spindle poisoning and it cause low cell viability and control abnormal cell proliferation.

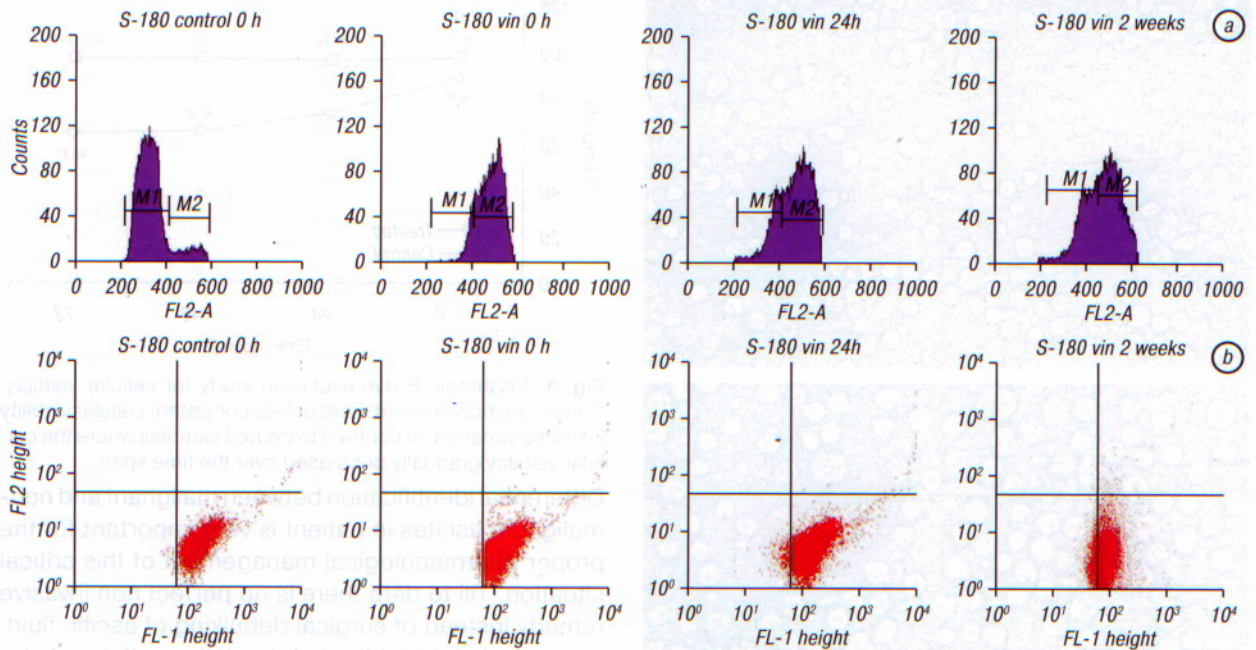


Fig. 5. Flowcytometric cell cycle study of untreated and vincristine treated malignant peritoneal effusion (a). Here, M1 stands for G1/S phase cells and M2 stands for G2/M phase cell population. Flowcytometric TERT expression of untreated and treated malignant peritoneal effusion (b)

Vincristine acts by binding rapidly and reversibly to microtubule ends and inhibiting the rate of tubulin addition. The tubulin-vincristine reversible binding lead us to study cell cycle pattern and its variation along with *in vivo* vincristine administration. It has been found that cell cycle status of malignant peritoneal ascites varied hugely in between treated and control animals. Immediate effect of vincristine was reflected by high (86.50%) G2/M phase blocked cells in case of treated animals whereas control animals showed usual distribution of various cellular phases. Again, we estimated cell cycle pattern after 24 h time gap and before the second dose of vincristine. We identified little depression in G2/M phase compartment and slight increment of G1/S compartment of peritoneal ascites in treated mice. The little depression in blocked G2/M phase compartment was due to the unstable binding of vincristine with tubulin. But it suggested that withdrawal event was limited within 24 h of single vincristine injection and a steady G2/M phase blocked cell population can be maintained if one can follow our protocol continuously. At the end of 2nd week, it has been found that a good proportion (60.99%) of G2/M blocked cells were evident, which correlated well with the tumor load regression through reduced cellular viability and increased life span of the treated malignant peritoneal effusion bearing mice.

In present study we have chosen flowcytometric TERT (telomerase reverse transcriptase) expression due to three reasons. First, telomerase activity assay is an useful adjunct for cytologic methods in differential diagnosis of peritoneal malignant and nonmalignant ascites and as we have chosen ascitic sarcoma-180 for our experimental peritoneal metastatic condition, henceforth flowcytometric TERT ex-

pression was evident in most the treated and untreated peritoneal malignant ascitic cells. Tumor cells escape programmed cell death through reactivation of Telomerase and these immortalized cells compensated for telomeric shortening at each cell division, which lead to progressive neoplastic evolution. In contrary, non neoplastic cells (like leukocytes, RBC, etc.) are not TERT positive and the actual TERT positive malignant cells were detected by flowcytometry based diagnostic platform and aid a good future diagnostic initiative in MRA detection.

Second, distinctly separated TERT positive malignant cells clearly showed the percentage of the TERT positive cells as a prognostic marker whose expression pattern changed over time and with vincristine administration. It was evident that intraperitoneal vincristine administration actually interfered cell cycle of malignant peritoneal ascites and synchronized at G2/M phase. Synchronization at G2/M phase limited the TERT expression as well as stopped the malignant cells to complete /exit cell cycle. From our study, it was found that TERT expression pattern almost depended on various cell cycle phase distribution. High TERT expression was found at 0 h in untreated and treated malignant ascites and it was usual due to presence of either high proportion of late G1 and S phase cells or early G2 phase cells in which telomere replication was under process. Cell cycle based TERT expression regulation in malignant peritoneal ascites was reflected in our 2nd week data where a stable G1/S and G2/M distribution signified a less aggressive TERT expression in comparison to initial 0 h and 24 h data. These studies further correlated with increased median survival time and increased life span of treated animals in comparison to the control. In this regard

it is clear that intraperitoneal vincristine administration has a good therapeutic modality along with partial TERT inhibition capacity.

Third, our innovative flowcytometric TERT expression study was quick, more accurate and easy, involved a limited number of steps and is free from contaminating leukocytes which are inevitable problem in PCR based TERT assay (TRAP assay).

At the end, we conclude that long term intraperitoneal administration of vincristine sulfate in small doses could be a good pharmacological intervention in case of malignant peritoneal ascites due to sarcomatosis as it indirectly reduced the level of TERT expression in malignant cells and increased the life expectancy of the diseased subject.

ACKNOWLEDGEMENTS

We are thankful to the Director, Calcutta School of Tropical Medicine.

REFERENCES:

1. Li C-P, Huang T-S, Chao Y, *et al.* Advantages of assaying telomerase activity in ascites for diagnosis of digestive tract malignancies. *World Journal of Gastroenterology* 2004; **10**: 2468–71.
2. Bilici A, Uygun K, Altun E, *et al.* Primary peritoneal spindle cell sarcoma presented with massive ascites: a case report. *J BUON* 2009; **14**: 721–3.
3. Oei TN, Jagannathan JP, Ramaiya N, *et al.* Peritoneal sarcomatosis versus Peritoneal carcinomatosis: imaging findings at MDCT. *Am J Roentgenol* 2010; **195**: W229–35.
4. Yokoi M, Hosokawa K, Funaki H, *et al.* A case of retroperitoneal dedifferentiated liposarcoma successfully treated with IFM and CDDP. *Gan To Kagaku Ryoho* 2009; **36**: 2114–6.
5. Colizza S, Di Maurizio P, Bracci F, *et al.* Diffuse peritoneal liposarcoma — report of one case. *J Surg Oncol* 1981; **18**: 147–51.
6. Leal R, Lewin M, Ahmad I, *et al.* Peritoneal Kaposi's sarcoma: a cause of ascites in acquired immunodeficiency syndrome. *Dig Dis Sci* 1994; **39**: 206–8.
7. Tangkijvanich P, Tresukosol D, Sampatanukul P, *et al.* Telomerase activity in human cancer. *Curr Opin Oncol* 1996; **8**: 66–71.
8. Runowicz C. Should patients with ovarian cancer receive intraperitoneal chemotherapy following initial cytoreductive surgery? *Nat Clin Pract Oncol* 2006; **3**: 416–7.
9. Armstrong DK, Bundy B, Wenzel L, *et al.* Intraperitoneal cisplatin and paclitaxel in ovarian cancer. *N Engl J Med* 2006; **354**: 34–43.
10. Dorr RT, Fritz WL. Cellular chemotherapy consideration in Cancer Chemotherapy Hand Book. Henry — Klinton publishers, London 1980; 3–18.
11. Joel S. The comparative clinical pharmacology of vincristine and vindesine: does vindesine offer any advantage in clinical use? *Cancer Treat Rev* 1996; **21**: 513–25.
12. Wall ME. Camptothecin and taxol: discovery to clinic. *Med Res Rev* 1998; **18**: 299–314.
13. Gidding CE, Kellie SJ, Kamps WA, *et al.* Vincristine revisited. *Crit Rev Oncol Hematol* 1999; **29**: 267–87.
14. Wang TH, Wang HS, Ichijo H, *et al.* Microtubule-interfering agents activate c-Jun N-terminal kinase/stress-activated protein kinase through both Ras and apoptosis signal-regulating kinase pathways. *J Biol Chem* 1998; **273**: 4928–36.
15. Stone AA, Chambers TC. Microtubule inhibitors elicit differential effects on MAP kinase (JNK, ERK, and p38) signaling pathways in human KB-3 carcinoma cells. *Exp Cell Res* 2000; **254**: 110–9.
16. Mabuchi S, Ohmichi M, Kimura A, *et al.* Inhibition of phosphorylation of BAD and Raf-1 by Akt sensitizes human ovarian cancer cells to paclitaxel. *J Biol Chem* 2002; **277**: 33490–500.
17. Subbaramaiah K, Hart JC, Norton L, *et al.* Microtubule-interfering agents stimulate the transcription of cyclooxygenase-2. Evidence for involvement of ERK1/2 AND p38 mitogen-activated protein kinase pathways. *J Biol Chem* 2002; **275**: 14838–45.
18. Premkumar RD, Arnold B, Mathas J, *et al.* Synergistic augmentation of vincristine-induced cytotoxicity by phosphatidylinositol 3-kinase inhibitor in human malignant glioma cells: evidence for the involvement of p38 and ERK signaling pathways. *Cancer Therapy* 2005; **3**: 407–18.
19. Jordon MA, Thrower D, Wilson L. Mechanism of inhibition of cell proliferation by vinca alkaloids. *Cancer Res* 1991; **51**: 2212–22.
20. Creasey WA. Modifications in biochemical pathways produced by the vinca alkaloids. *Cancer Chemotherapy Res* 1988; **52**: 501–7.
21. Sheppard JR. Effects of vinca alkaloids on cyclic AMP metabolism of mouse splenic lymphocytes. *Contrib Oncol* 1980; **6**: 27–36.
22. Bernstam VA, Gray RH, Bernstein IA. Effect of microtubule disrupting drugs on protein and RNA synthesis in *Physarum polycephalum amoebae*. *Arch Microbiol* 1980; **128**: 34–40.
23. Da M-X, Wu X-T, Guo T-K, *et al.* Clinical significance of telomerase activity in peritoneal lavage fluid from patients with gastric cancer and its relationship with cellular proliferation. *World J Gastroenterol* 2007; **13**: 3122–7.
24. Hiyama E, Yokoyama T, Tatsumoto N, *et al.* Telomerase activity in gastric cancer. *Cancer Res* 1995; **55**: 3258–62.
25. Greider CW, Blackburn EH. A telomeric sequence in the RNA of *Tetrahymena* telomerase required for telomere repeat synthesis. *Nature* 1989; **337**: 331–7.
26. Kim NW, Piatyszek MA, Prowse KR, *et al.* Specific association of human telomerase activity with immortal cells and cancer. *Science* 1994; **266**: 2011–5.
27. Shay JW, Wright WE. Telomerase activity in human cancer. *Curr Opin Oncol* 1996; **8**: 66–71.
28. Yakoob J, Hu GL, Fan XG, *et al.* Telomere, telomerase and digestive cancer. *World J Gastroenterol* 1999; **5**: 334–7.
29. Zhu X, Rakesh K, Mandal M, *et al.* Cell cycle — dependent modulation of telomerase activity in tumor cell. *Proc Natl Acad Sci USA* 1996; **93**: 6091–5.
30. Bairy KL, Satinath S, Jagetia GC, *et al.* Evaluation of intraperitoneal vincristine in malignant peritoneal effusion. *Ind J Physiol Pharmacol* 2003; **47**: 270–8.